

# The Pushpanjali connect

Quarterly Newsletter of Pushpanjali Medical Centre

July - September 2018, Vol.1

## Editorial

Dear friends,

Greetings from the editorial team.

Charged by Dr. Vinay Aggarwal's indomitable spirit, we at Pushpanjali Medical Centre are happy to reintroduce our popular Newsletter, "The Pushpanjali Connect". As it was in its earlier editions, so also in its new 'avatar', it is going to be a reflection of what PMC stands for.

We will bring you interesting clinical cases and diagnostic dilemmas faced at PMC, together with new treatment approaches, especially if they required multi-disciplinary care. The hallmark of PMC has always been teamwork and we will show how we have benefited by it.

Each newsletter will introduce you to the doctors of one particular specialty and showcase some recent achievement of that department. Contemporary issues like medicolegal tips will find a place. Supportive treatment like dietary advice and physiotherapy will also be there.

In our quest for excellence we regularly conduct CME's for doctors, nurses & support staff about which we will keep you updated.

At PMC we take our social responsibility very seriously. So, some outreach program, out of the many ongoing ones, will find mention.

The heart of PMC is the 'Pushpanjali family', of which we are very proud. After working hard, we relax together, whether it is during our quarterly kitty parties or our annual trip. All festivals are celebrated and so is the achievement of any individual member. A short while back we lost our dear Dr. Mamta Grover. Read this newsletter to find out what we have done to keep her memory alive.

Times have changed but the desire and the necessity to keep abreast of all that is happening in our own institution prevails and through this newsletter, we will try to keep you updated. So read this newsletter and look out for the next. Suggestions are welcome.



A-14, 15, Pushpanjali, Vikas Marg Extn., Delhi-110092  
Phone: 011- 43075600 | E- Mail: info@pushpanjalimedicalcentre.co.in  
Website: www.pushpanjalimedicalcentre.co.in

### Editorial Board

Dr. Anita Jain  
Dr. Karun Jain  
Dr. Garima Aggarwal

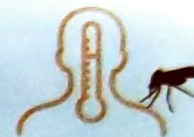## A CASE WITH A DIFFERENCE

### TB is not the only masquerader

Dr. Amish Bhutani, Associate Consultant, Internal Medicine

A 65-year-old male patient presented to PMC with complaints of low-grade fever, cough & decreased appetite for 2 months.

The fever was intermittent, spiked at 101°F and was associated with chills. Cough appeared one week after the onset of fever and was non-productive initially. He took treatment from a local doctor but was not relieved. He started having expectoration, which was muco-purulent and about 20-25 ml per day in quantity. There was no H/O hemoptysis, throat pain, shortness of breath or chest pain. His appetite decreased with resultant loss of weight and loosening of clothes. After multiple consultations, he visited Pushpanjali Medical Centre.



On examination, he was pale, under-nourished and febrile, with temperature 101°F, pulse rate 90/min and BP 108/70mm Hg. His SpO2 was 94% on room air. He had Grade 2 clubbing but no cyanosis, icterus, pedal edema or lymphadenopathy. Evaluation of the respiratory system revealed harsh vesicular sounds with pleural rub on the right basal and right mammary region. Cardiovascular, neurological and abdominal examination did not reveal anything significant.

A provisional diagnosis of right lower zone consolidation suggestive of atypical Koch's was made and he was admitted for further investigation and treatment. On clinical suspicion, Ceftriaxone and Clarithromycin were started along with supportive treatment.

His blood investigations showed Hb 9gm%, Transferring/saturation <10%, TLC 13,500/mm<sup>3</sup>, predominantly neutrophils and an ESR of 86mm in 1st hour. His sputum examination showed Gram positive cocci and was negative for AFB.

HRCT of the thorax was done for further evaluation. The CT report revealed a hypo-echoic lesion measuring 55ml on the postero-superior surface of the right lobe of the liver with no liquefaction. Minimum pleural effusion was seen on the right side. Lung parenchyma was normal, with no lymphadenopathy.

A diagnosis of ruptured liver abscess was made. Ultrasound corroborated the same. Amoebic serology was also positive.

**Treatment:** The patient was treated with Metronidazole and Chloroquine to which he responded.

**Final diagnosis:** Amoebic liver abscess with rupture into right pleural cavity with iron deficiency anemia.

Of late, there has been a varied presentation of liver abscesses. Pulmonary symptoms are not uncommon. Hence, liver abscess must also be considered an important differential diagnosis while investigating a patient with suspected lower respiratory tract infection.

## DIETICIAN'S TIPS



### Eating healthy during pregnancy



Ms. Pinky Sharma, Dietician

1. Don't forget breakfast.
2. Eat food with high fiber content eg-vegetables, fruits & sprouts.
3. You need carbohydrate, protein & fat in balanced amounts.
  - **Carbohydrate** - (1800-2100 kcal/day) can be got from wheat flour, rice, other cereals, pulses, potatoes, pasta & bread.
  - **Protein** - (1gm/kg body wt/day) is available in milk & milk products, tofu, soyabea lentils, egg, lean meat & cheese.
  - **Fat** - (20% - 30% of total calories) can be obtained from oil, ghee, butter & nuts.
4. **Calcium** - (1000mg/day) is found in milk, cheese, curd, yoghurt & guava.
5. **Iron** - (60mg/day) can be obtained from cereals, jaggery, spinach, lean meat, fruits, pomegranate, banana & guava.



You can ask me to make a tasty and nutritious diet chart for you.

## Department of Obstetrics & Gynaecology

### Consultants at a glance:



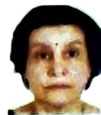Dr. Sangeeta Goel



Dr. Anita Jain



Dr. Anita Aggarwal



Dr. Bakul Arora



Dr. Sowjanya Aggarwal



Obstetrics is the only branch of medicine in which the 'patient', i.e. the expectant mother, is happy to be a patient. It is a department of hope, pain and joy for the patient and nail biting tension and minute-to-minute decision making for the obstetrician. Backed by a dedicated team of paediatricians and anaesthetists and a well-equipped labour room and operation theatre, we manage all high & low risk pregnancies. The post delivery care given by our nurses, dieticians and physiotherapists is much appreciated by our patients.

On the gynaecology front, we cater to all gynae problems from adolescence to senescence. We do all major & minor surgical procedures and ever since Dr. Sowjanya has joined the team, we are performing very advanced hysteroscopic and laparoscopic surgery as well. Family planning procedures ranging from conception to high risk abortions and treatment of infertility were always being done and now we have added IVF to our armamentarium.

### An interesting case

A 38 years old female patient, P2L1 with a history of 2 LSCS deliveries, presented to PMC OPD as a case of failed IVF.

She had lost her second child in a road accident one year ago and was desperate to conceive. Since her husband had undergone vasectomy after her second childbirth, spontaneous conception was not possible. She had therefore undergone IVF six months ago at another IVF centre but with no success.

On vaginal examination, her uterus was irregular and of 8-10 weeks size. On investigation, Ultrasound revealed a posterior wall myoma, 63x70 mm in size, indenting the endometrium and her AMH was 1.2 pmol/l.

In view of one failed IVF cycle, a decision was made to do laparoscopic myomectomy followed by ICSI (Intracytoplasmic sperm injection) with TESA (Testicular Sperm Aspiration).

She was admitted to PMC and laparoscopic myomectomy was performed. The procedure was uneventful and she was discharged on the next day.


She was taken up for IVF after 6 weeks. She was downregulated by long protocol and then stimulated for 11 days with HMG (Human menopausal gonadotropin).

Ten oocytes were retrieved. ICSI was done with seven mature oocytes out of which five got fertilized and two were transferred. She tested beta HCG positive after 14 days. At 18 weeks gestation she developed GDM and had to be put on insulin. At 27 weeks she developed PIH & was treated with labetalol. She was closely monitored but developed severe PET because of which she had to be delivered prematurely by LSCS at 34 weeks gestation. The baby was shifted to NICU at PMC and was discharged after 2 weeks. Both the mother and the baby girl were healthy at the time of discharge.

### Medico legal recommendations regarding issuing of medical certificate:-

*Dr. Karun Jain, Ortho Surgeon*

1. Never give it for more than 15 days.
2. See Patient again after 15 days and re issue.
3. Even in repeat cases, make sure that he or she is the patient. Identify the patient by photo ID Card, and then issue to the patient directly & not to the attendants.
4. Avoid issuing certificate for diseases which you are not treating / or trained to treat. (Other Disciplines)
5. Describe the disability as best as you can even if you don't know how to grade it.
6. **MOST IMPORTANT "IT IS A LEGAL DOCUMENT"**  
Even if you print otherwise, it is admissible in a court of law & you cannot say that, it was not intended for legal purposes."
7. The Certificate must address a particular person like..."Principal of school" "Employer" etc. Don't write "To whomsoever it may concern".
8. Never give from back date
9. Never give on days other than your OPD days.
10. Never give fitness certificate on advanced date or back date.
11. Never give fitness certificate, if Medical Certificate for rest was given by somebody else.
12. Give if you can justify the disease or ailment and the duration for that particular disease.
13. Physical presence of the patient is essential because the patient may be abroad or in heavenly abode. So never write PNB (Patient NOT Brought)
14. You are a responsible Class I gazetted officer verifying the physical presence and attendance. The certificate issued by you is a legal document which is valid in a court of law to justify the presence or absence of the accused or deceased at the scene of crime.



## PMC ACADEMIA

### Academic Lectures Organized at Pushpanjali Medical Centre

Date	Title	Speaker
31st August 2018	Essential Care at Birth	Dr. Karun Jain
15th July 2018	Kangaroo Mother Care	Dr. Vineet Jain
5th July 2018	Basal Insulin in the treatment of T2DM	Dr. Ashok Grover
20th June 2018	Emergency Trauma Management: Do's & Don'ts	Dr. Karun Jain
10th June 2018	NG Tube Insertion in New Born	Dr. Vineet Jain
8th June 2018	Role of Neutrophils in Severe Sepsis	Dr. Manish Singh
7th June 2018	Role of Vitamin E in muscle cramps	Dr. Ashok Grover

# Congratulations!

**National Accreditation Board  
for Hospitals & Healthcare Providers**

Certificate of Accreditation

Pushpanjali Medical Centre  
A-12 & 13, Subhash, Okhla, New Delhi-110022

has been assessed and found to comply with NABH  
accreditation requirements for Small Health Care Organisations  
(SHCO) Second Edition, April 2014.

This certificate is valid for the Scope as specified in the  
annexure subject to continued compliance with the  
accreditation requirements.

Valid from: June 21, 2018

Valid till: June 20, 2021

Certificate No.  
SHCO/18-098

Chief Executive Officer

Chairman



**Pushpanjali**  
Medical Centre

*Pushpanjali Medical Centre  
is Re-accredited by National Accreditation  
Board for Hospital (NABH)  
from June 21, 2018 till June 20, 2021*

## DR SHARDA JAIN'S – MY PMC JOURNEY



**Dr. Sharda Jain**

M.D. (PGIMER), MNAMS, FICOG, FIMSA,  
DHM, QM & AHO PGDMLS (SYMBIOSIS)

After teaching for two decades at PGI MER Chandigarh & Lady Harding Medical College – my destiny brought me to the journey of private practice. I became part of PMC in March 1990 i.e. from day one of its inception.

I was well trained & confident of my ability to meet any clinical challenges & was also firm never will compromise my values.

I was very passionate to -

- To Add value & get things done even if I have to step out of my comfort zone.
- Give 100% towards my work.
- Being a teacher, do hand holding of my colleagues & youngsters by sharing knowledge & upscale skills.

3 decades is a long time in a bid to nurture & develop institution; strengthen relationship with community of this region & staff members of Pushpanjali family. My long journey has been parallel to the Journey of PMC. I always gave my best to nurture this institution brick by brick with a vision to make it a bench mark in Gynaecology & Pregnancy care. I was always proactive

never took anything for granted, always thinking about what could go wrong & what do to about it . We were able to manage all types of cases & had excellent support from other departments. We never indulged in or promoted any referral practice.

My obsession that don't be static & putting extra work specially in patient care & practicing ethical evidence based medicine made me popular respected name in east Delhi both in public & among doctor colleagues of all specialities.

I was paranoid about Timing & scheduling of surgical cases. People could set watch by my arrival. A success of handling difficult cases was always celebrated as a team success. By god grace, year after year in any success parameter I remained Top. I enjoyed excellent & wonderful relationship even with the lower most employee specially lady employees could bank on my support in PMC.

It is almost a decade that I stopped OPD at PMC – staff still comes to me for consultation, advice & guidance both for medical reasons & guidance for their children.

Thank you PMC for appreciating my contributions in making PMC of Today & nurturing it's core values.

*With best compliments from*

# **S.S. SURGICALS**

**STOCKIT: B.D, ROMSON, HMD, PROTEX, BARD, RUSH, MEDIKIT,  
JOHNSON, OSTER, SUTURE, INDIA & DIAGNOSTIC PROD.**

**Address: 703, Street No.13, S.B.S. Colony Karawal Nagar, Delhi-110094  
Tel.No. 9810675089, 9953540420, 9999932531 | E-mail : s.s.surgicals703@gmail.com**

*With best compliments from*

# **GLOBAL INDIA HEALTHCARE**

**A HOUSE OF SURGICAL PRODUCTS**

**Address: 2679, Gali No.5, Mahaveer Block, Bholanath Nagar,  
Shahdara, New Delhi-110032, Tel.No. 7703898980**

*With best compliments from*

**Alniche  
Life Sciences Pvt. Ltd.**

## PUSHPANJALI FAMILY

### Mamta

*Dr. Ashok Grover, Sr. Consultant Internal Medicine*



We come across many people in life, but only a few leave an indelible impression in our hearts and minds. Dr. Mamta Grover was one such person. A woman of many talents and a will of steel. Not only was she a wonderful Paediatrician, but was also a brilliant cook, writer, author and an artist. Gardening was also one of her many talents that she excelled in.

In the loving memory of Dr. Mamta Grover, we at Pushpanjali Medical Center have rechristened her beloved Nursery and NICU as 'MAMTA' to honor her indomitable spirit.



## HELPING HAND

We at Pushpanjali Medical Centre take our social responsibility very seriously & are watching out for our community.

### Kerala Relief

God's own beautiful country –Kerala was recently in a state of devastation. Ravaged by floods with lakhs of people displaced to relief camps and countless dead, Clinics, Nursing Homes and hospitals also suffered tremendous damage. We at PMC got together & contributed a total of Rs.2.5 lakhs towards Kerala relief fund.

### PMC's Beti Padhao Yojana

PMC is executing the Beti Padhao Yojana for 2 years now to provide regular & gracious help to the minor girl children of a number of its employees by providing regular monthly financial assistance to them in the name of the girl child.

## I AM PASSIONATE ABOUT ....

### Dr. Gaurav's Passion - Model Car Collection

Collecting Scale Model Cars is not just a hobby but a passion that I've been pursuing since many years. I have always been crazy about cars since my childhood & the same passion made me start this hobby of collecting 1:18 Scale Model Cars. A Custom made display has been created in the house to showcase the entire model car collection. The collection has American Muscle Cars of 1960's & 70's Like Ford Mustang, Chevrolet Camaro, Pontiac GTO, AMC Rebel & my Absolute favourite is a Black Dodge Charger 1969 Model. The collection also has American Classic cars from 1960's Like the famous Impala, Chrysler 300, Cadillac, Imperial etc.

My current Favourite in the collection is Black Chevrolet Bel Air 1957 Model that I recently purchased. I also have a good collection of old classic Mercedes 280 E series in my collection. Another section of collection has Formula 1 cars, Super cars, French Cars etc.

I normally spend time on Sunday's just admiring and taking care of these cars & intend to continue my collection by adding more world famous car models. These Model cars are actual scale replicas of the original cars in the scale 1:18 & are authorised by the Brands. Most of these model cars have been purchased whenever we travel abroad as the quality is much better.

Thank you for giving me an opportunity to share my passion in the first PMC Bulletin .



# CELEBRATIONS

## Onam Celebrations

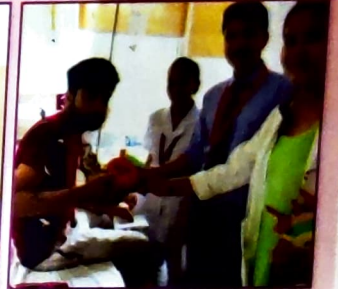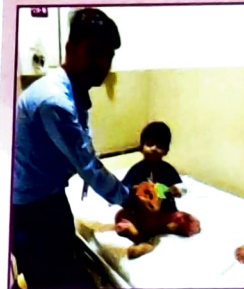Acknowledging the need for our staff to feel at home and enjoy, Onam Celebrations at PMC get bigger every year. This year we celebrated Onam on 22nd Aug, 2018 with a grand function at Ashoka Bhawan. The crowd was enthralled by the enthusiastic performances put up by PMC staff. Some of the highlights were the traditional onam dance performed by the nurses & an action packed medley 'India' dance performance by some staff members.



## Independence Day Celebrations



## Nutrition Week Celebrations



## EMPLOYEES OF THE MONTH

April 2018



Ms. Anjitha Shaji

June 2018



Ms. Sherni Kurjuman

August 2018



Ms. Dileena Mol JC

## NEW JOINEE'S

### Dr. Shailesh Chandra Sahay

MBBS (Gold Medalist), MS (MAMC, New Delhi), M.Ch. (Urology, AIIMS, New Delhi)  
Awardee European Fellowship (EUREP, Czech Republic, Prague)

**Sr. Consultant Urologist** | OPD Timings: 5pm to 6pm (Tue & Sat)

### Dr. Garima Aggarwal

MD (Internal Medicine), DM (Nephrology)

**Consultant Nephrologist** | OPD Timings: 10am to 12pm (Tue & Sat)  
4pm to 5pm (Thu)

### Dr. Amish Bhutani

MBBS, MD (Internal Medicine)

**Consultant Internal Medicine** | OPD Timings: 11am to 1pm (Mon to Sat)

### Dr. Deepika Verma

MBBS, MD (Psychiatry)

**Consultant Psychiatrist** | OPD Timings: 12pm to 1pm (Mon to Sat)

### Ms. Ayushi Madaan

MA, M.Phil

**Clinical Psychologist, NLP Practitioner**

OPD Timings: 12pm to 2pm (Mon to Sat)



Over **4 million**  
cord blood units  
are stored worldwide

More than **50,000**  
cord blood transplants  
occur every year

**80+**  
approved  
treatments

**500+**  
clinical trials

“**Stem cells** are scientific innovation with ability to change lives of people & improve their **well-being.**”

**CRYOVIVA**, as India's foremost umbilical cord blood stem cell bank is fully aware of it's responsibility by providing easily accessible quality services to the masses.

**Processing Technology**

US FDA approved automated processing technology

**Quality Standards**

State-of-the-art storage & processing technology with class 10,000 clean rooms for highly sterile sample preparation

**SALIENT FEATURES**

**Accreditations**

AABB, FACT-Netcord, DCGI, NABL, ISO, CAP, GMP/GLP

**Trust**

Trust of 2L+ parents

**Preserve your baby's STEM CELLS at birth and protect your family's long term Health**



**Cryoviva Biotech Pvt. Ltd.**

129, Pace City-1, Sector 37, Gurgaon Haryana-122001, (India)  
Tel. No.: 0124-3341301 - 305, Toll Free No.: 1800 3002 2796  
Website: www.cryoviva.in, Email:marketing@cryoviva.in

CIN No.: U85195DL2005PTC137768; Registered Office: F-2/7, Okhla Industrial Area, Phase I, New Delhi-110020

To know more:  
**+91-9999 67 3620**

ॐ

स्वैभवन्तु सुखिनः सर्वे सन्तु निरामयाः ।  
सर्वे भद्राणि पश्यन्तु मा कश्चिद्दुःखमागमवेत् ॥

*With best compliments from*

# GIRIDHAR CHEMISTS

*A Trusted Name in Medicines & Surgicals*

**Home Delivery Services Available**

**Address:**

A-14, 15, Pushpanjali, Vikas Marg Extn., Delhi-110092

Phone: 011- 22376610, 49401679

E- Mail: girdharchemists@gmail.com

## WORK HARD, PARTY HARDER

### Pushpanjali Kitty

*Dr. Rajesh Dhall, Sr. Consultant Anesthetist*

Pushpanjali Family Kitty has been running almost since the inception of this hospital. It is an event which is very sought after. Almost all the Consultants are part of this Family Kitty. It gives a unique opportunity where consultants, their spouses and children participate & interact. The Consultants who look very busy and serious while in the hospital are completely changed personalities in kitty where they sing dance & enjoy every moment. The Pushpanjali Family Kitty is held once every 3 months & is managed by Dr. Yogesh Jhamb & Dr. Rajesh Dhall.



### Dubai

*Dr. Deepak Pande, Sr. Consultant, Paediatrics*



A vacation is always fun but it becomes a riot when you go with people with whom you have been working for decades.

Our Dubai trip was one such exotic holiday. The lovely weather, locales and being off from work and mobiles brought out the 'doosra' side of our natures which we never saw while at work. The Burj Khalifa, Dubai Mall, Desert Safari, Dhow Cruise, Palm Beach Resorts, Gold Souk would remain etched in our minds. Thanks to the 'selfie-man' who gave us many memorable impressions. The exclusive invite at the pub was adventurous as it entailed sneaking out and then creeping back into the bed without the wife's getting to know!

All arrangements of transport, accommodation and scheduling were very well executed evidently due to meticulous planning at home. Thanx to Dr. Vinay and Ms. Shweta for the initiative and the planning.

No doubt we are looking forward to the next one.

Ab sher ke muh mein khoon jo lag gaya hai!!!



## WORK HARD, PARTY HARDER

### Pushpanjali Kitty

*Dr. Rajesh Dhall, Sr. Consultant Anesthetist*

Pushpanjali Family Kitty has been running almost since the inception of this hospital. It is an event which is very sought after. Almost all the Consultants are part of this Family Kitty. It gives a unique opportunity where consultants, their spouses and children participate & interact. The Consultants who look very busy and serious while in the hospital are completely changed personalities in kitty where they sing dance & enjoy every moment. The Pushpanjali Family Kitty is held once every 3 months & is managed by Dr. Yogesh Jhamb & Dr. Rajesh Dhall.



### Dubai

*Dr. Deepak Pande, Sr. Consultant, Paediatrics*



A vacation is always fun but it becomes a riot when you go with people with whom you have been working for decades.

Our Dubai trip was one such exotic holiday. The lovely weather, locales and being off from work and mobiles brought out the 'doosra' side of our natures which we never saw while at work. The Burj Khalifa, Dubai Mall, Desert Safari, Dhow Cruise, Palm Beach Resorts, Gold Souk would remain etched in our minds. Thanks to the 'selfie- man' who gave us many memorable impressions. The exclusive invite at the pub was adventurous as it entailed sneaking out and then creeping back into the bed without the wife's getting to know!

All arrangements of transport, accommodation and scheduling were very well executed evidently due to meticulous planning at home. Thanx to Dr. Vinay and Ms. Shweta for the initiative and the planning.

No doubt we are looking forward to the next one.

Ab sher ke muh mein khoon jo lag gaya hai!!!





**Pushpanjali**  
Medical Centre



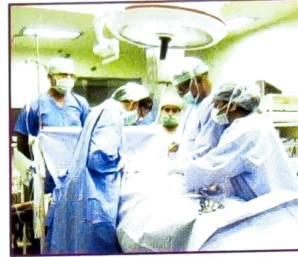## Multi Speciality Hospital



Reception



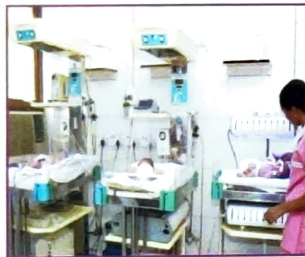OPD



Operation Theatre



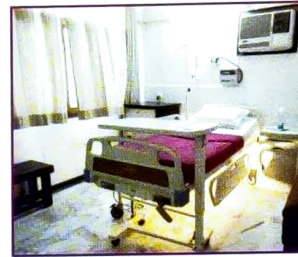Labour Room



Nursery



ICU



Single Room



Cafeteria

### Centre For

**Mother & Child Care**

**Laparoscopic Surgery**

**Kidney Stones & Prostate Surgery**

**Medical Intensive Care**

**Joint & Trauma Surgery**

**Dialysis Unit**

### Services

- Cardiology
- Dentistry
- Dermatology
- ENT
- Gastroenterology
- Homeopathy
- IVF & Infertility
- Laparoscopic Surgery
- Laboratory Medicine
- Medicine
- Nephrology & Dialysis
- Neurology
- Neuro Surgery
- Obs & Gynae
- Oncology
- Ophthalmology
- Orthopedics
- Pediatrics
- Psychiatry
- Plastic surgery
- Physiotherapy
- Radiology
- Sports Medicine
- Urology

**PMC Helpline: 011-43075600**

**Emergency: 011-43075657**

**A-14, Pushpanjali, Vikas Marg Extn., Delhi - 110092**

**E-mail: [info@pushpanjalimedicalcentre.co.in](mailto:info@pushpanjalimedicalcentre.co.in) | [www.pushpanjalimedicalcentre.co.in](http://www.pushpanjalimedicalcentre.co.in)**